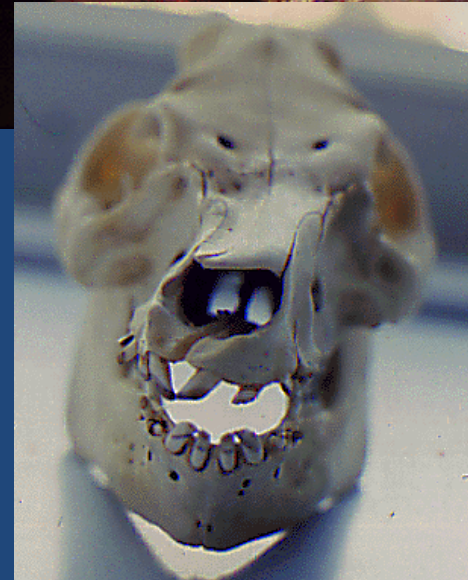




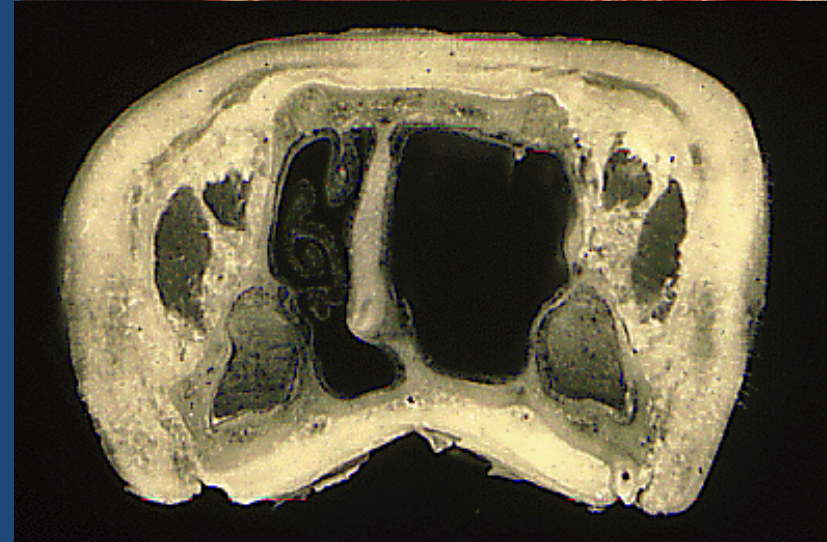
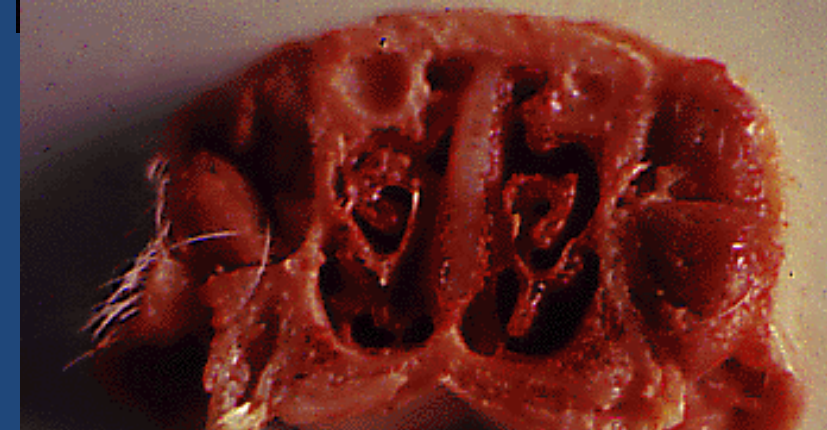
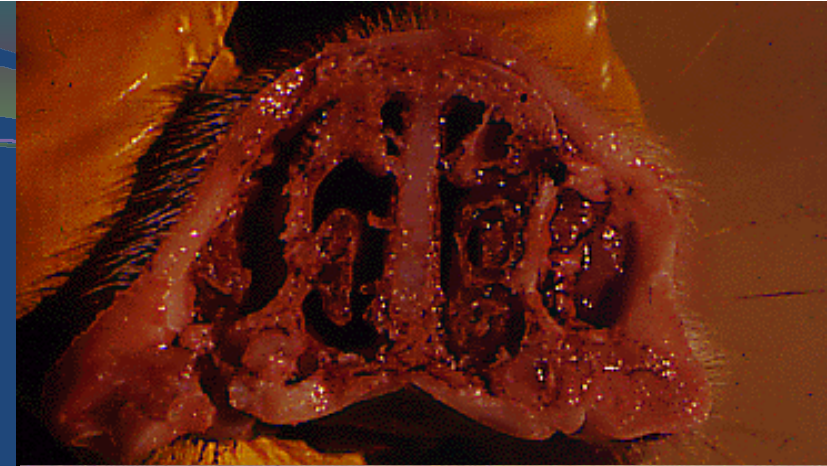
# Disorders of the head

John Carr  
Murdoch University  
Portec Australia

# Infectious Progressive Atrophic Rhinitis




## Postmortem findings

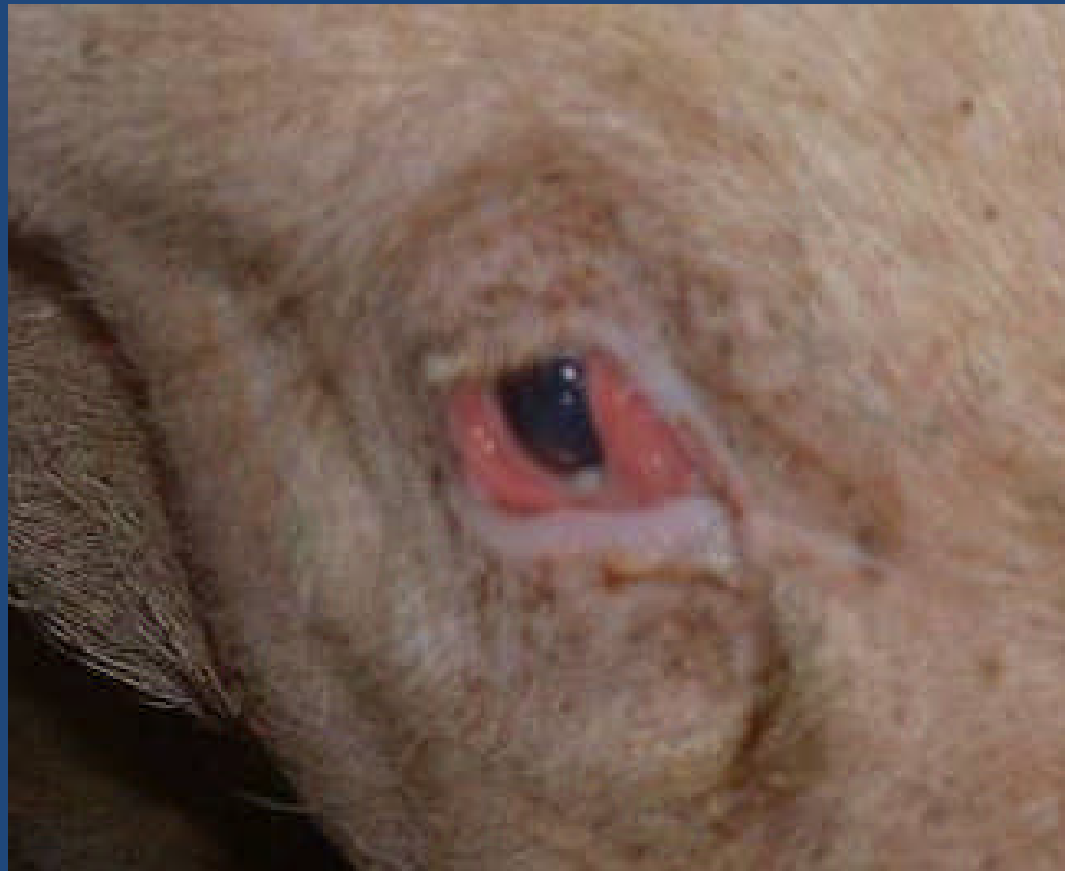

## Treatment and control

- Wet feed
- Vaccination
- Depopulation



## Conjunctivitis

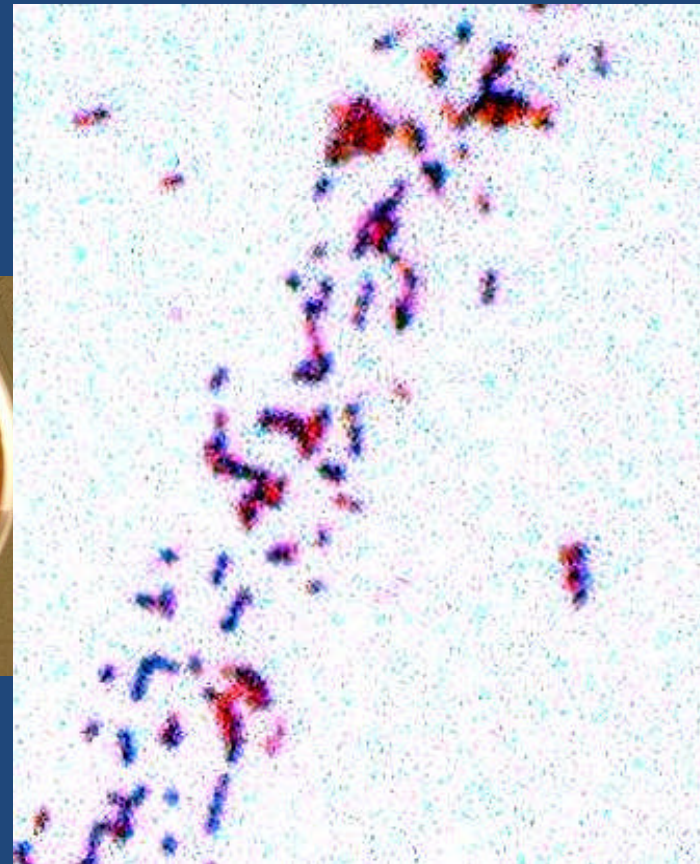
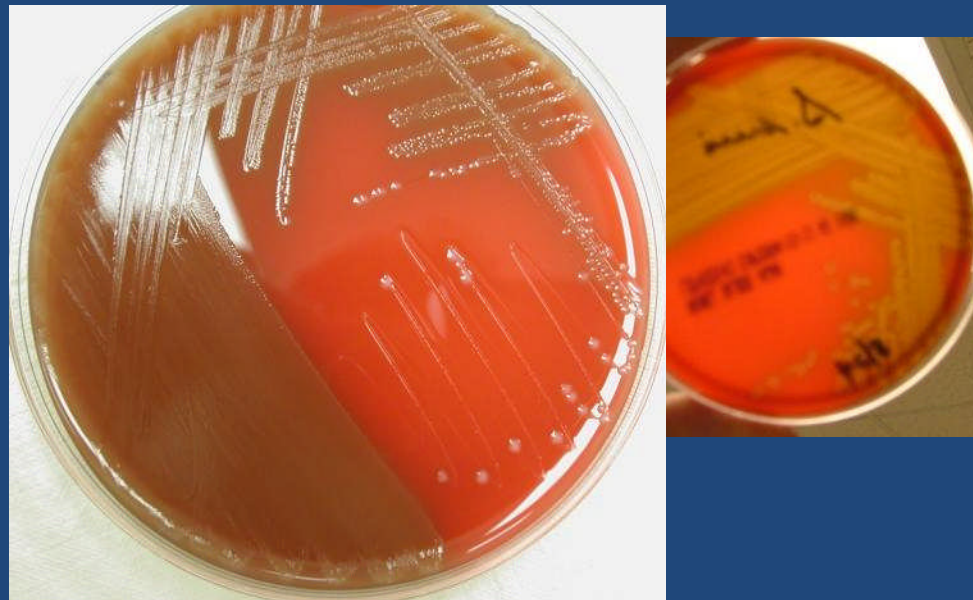

# Meningitis

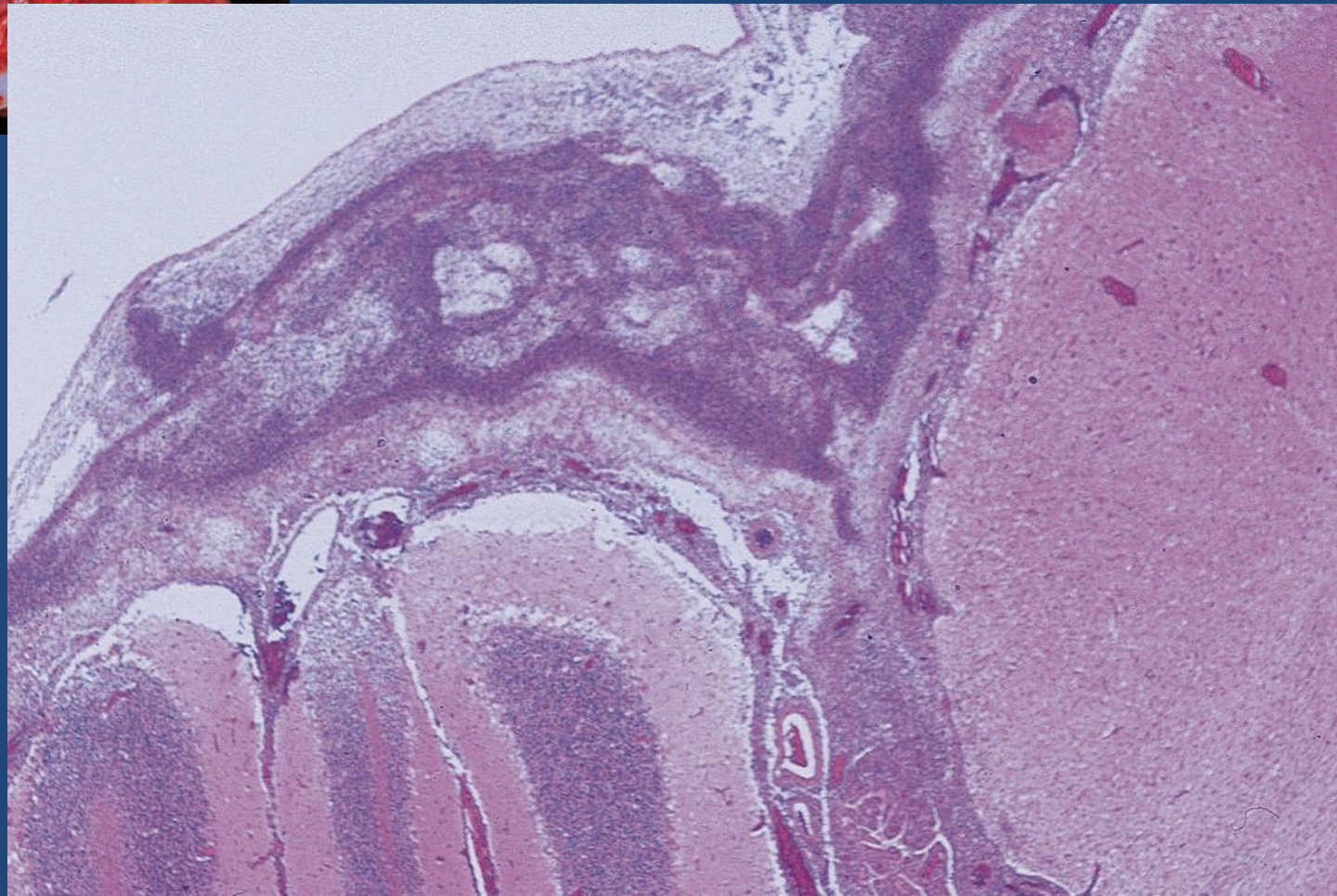
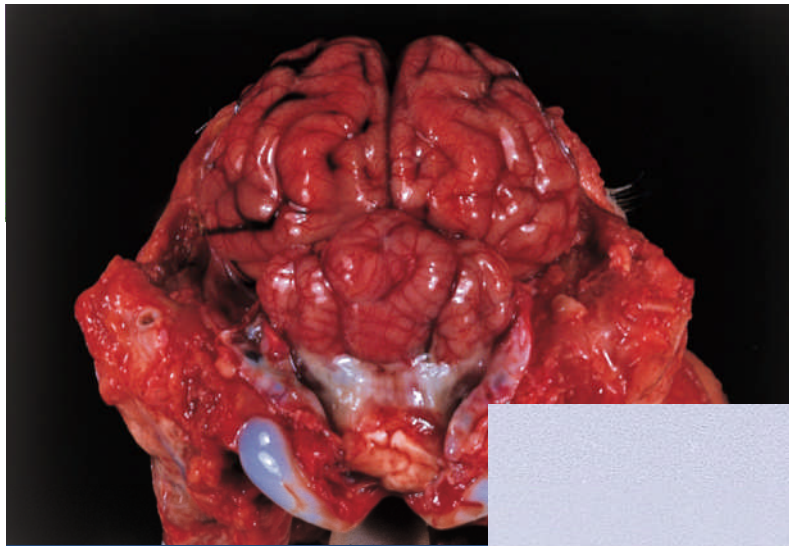


## Causal agents

- *Streptococcus suis* II



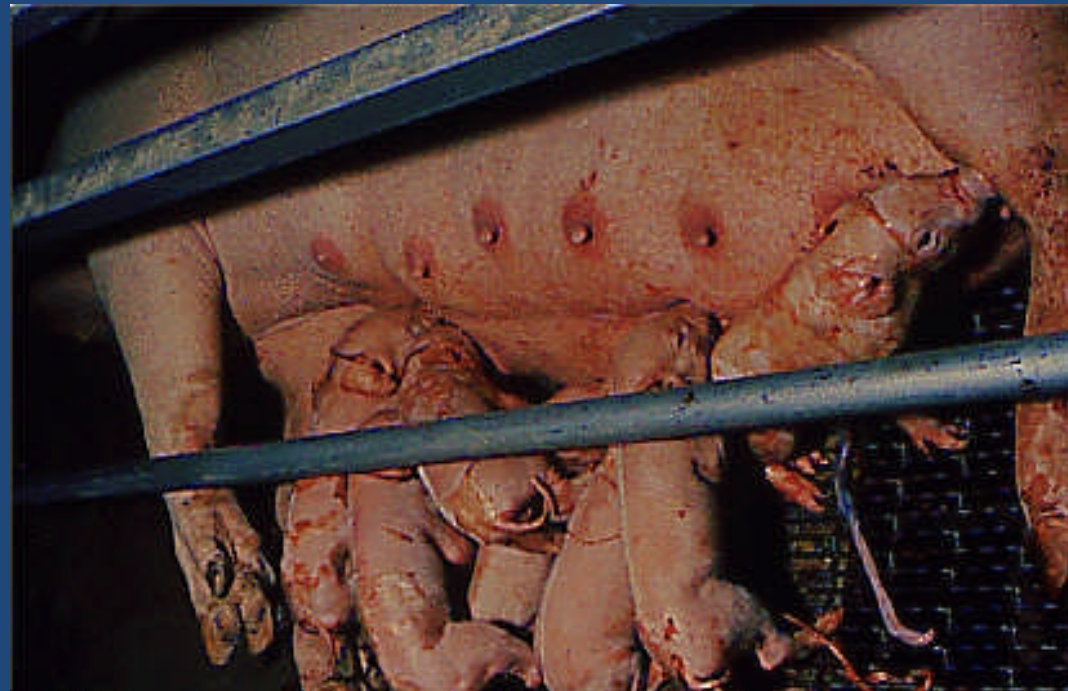
- But also other agents – *Haemophilus parasuis*
- Gram stain of section



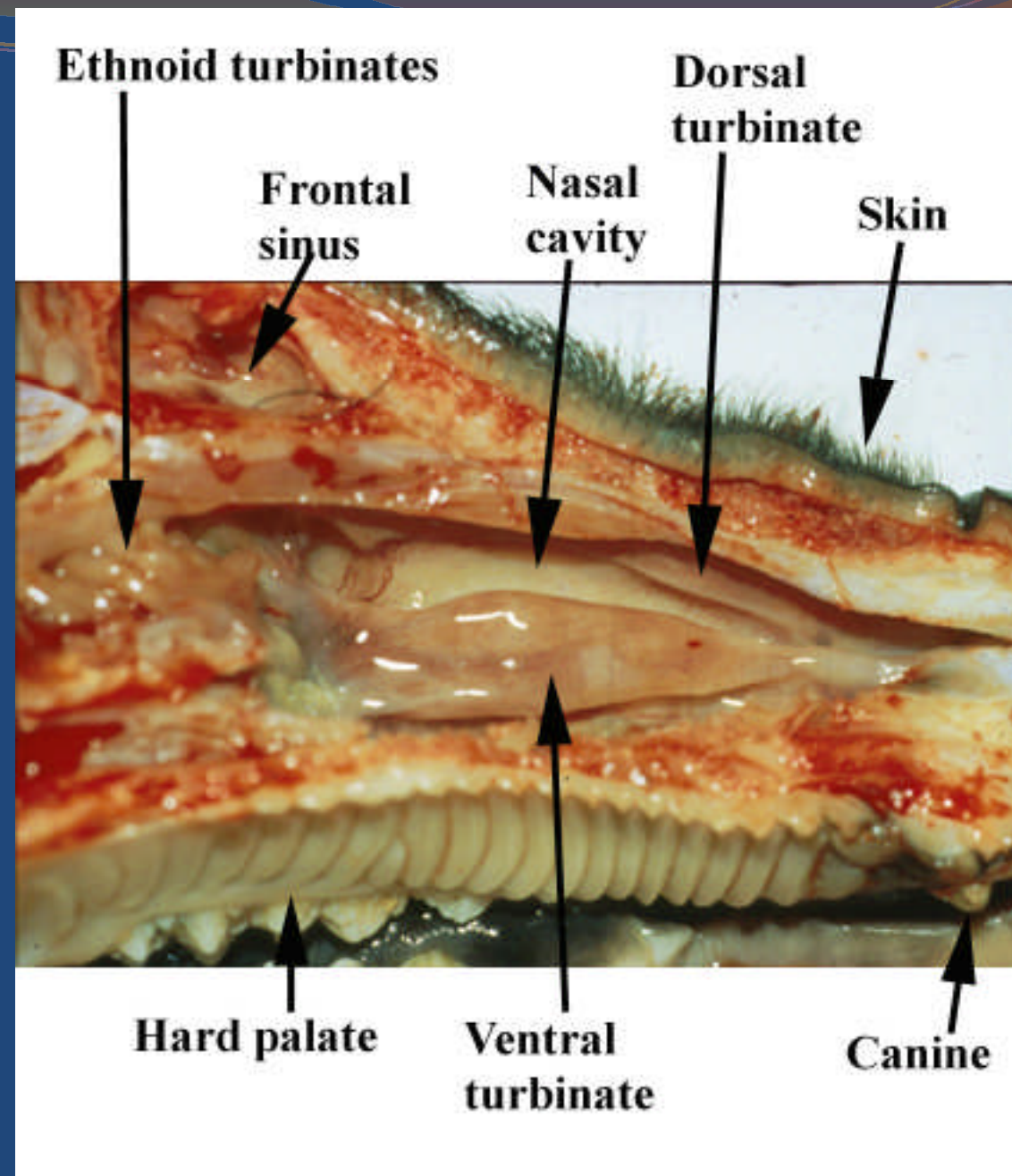
## Treatment and control

- Ceftiofur/Penicillin
- Resolve management errors
  
- Note Zoonotic condition

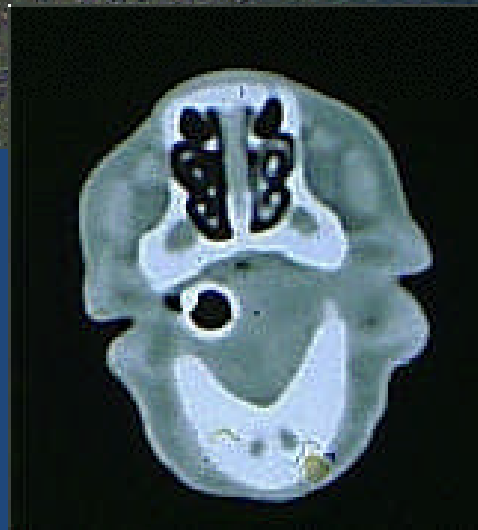## Congenital tremor



Post-weaning sneezing



# Middle ear disease



## Aural haematoma

